



# GHAPP

Gastroenterology & Hepatology  
Advanced Practice Providers

**2020 Third Annual National Conference**

**November 19-21, 2020**

Red Rock Hotel – Las Vegas, NV



**GHAPP**

Gastroenterology & Hepatology  
Advanced Practice Providers



# How to Perform a Proper Rectal Exam

**Nastassja Williams, MSN, APRN, FNP-BC**

Digestive Health Center

Northwestern Memorial Hospital, Chicago, IL

# Disclosures

---

All faculty and staff involved in the planning or presentation of continuing education activities provided by the Annenberg Center for Health Sciences at Eisenhower (ACHS) are required to disclose to the audience any real or apparent commercial financial affiliations related to the content of the presentation or enduring material. Full disclosure of all commercial relationships must be made in writing to the audience prior to the activity. Staff at the Annenberg Center for Health Sciences at Eisenhower and Gastroenterology and Hepatology Advanced Practice Providers have no relationships to disclose.

# Disclosures

---

**Nastassja Williams, MSN, APRN, FNP-BC**

Consultant: Guidepoint, Clinical Area- *H. pylori*,  
Colon cancer screening

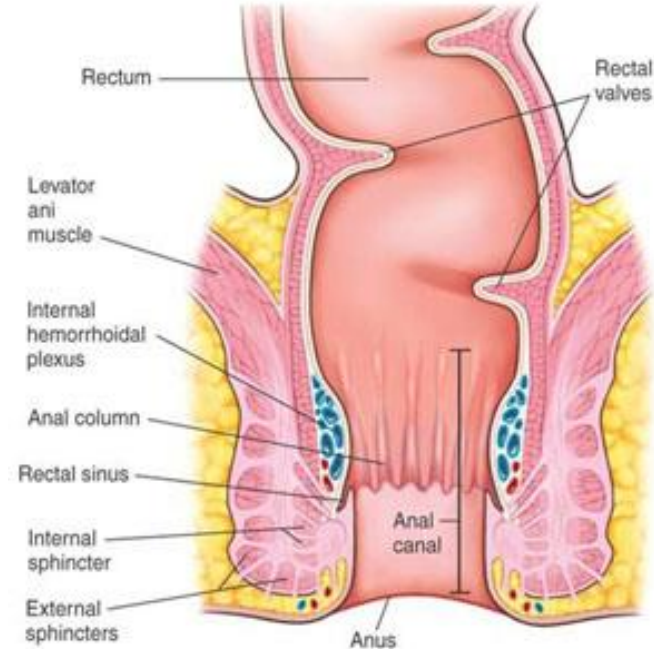
# Objectives

---

- Review the anatomy and physiology of the anus and rectum
- Evaluate indications to perform a digital rectal exam
- Discuss 10-step approach to performing a rectal exam

# Anatomy and Physiology

- Rectum begins at the termination of the sigmoid colon about 12 cm from the anal verge
- Two muscle bundles
  - **Internal anal sphincter** is an enlargement of the circular smooth muscle of the colon and **functions involuntarily**
  - **External anal sphincter** consists of striated muscle bands under the **voluntary control** of the puborectalis muscle
- Rectum has the same innervation as the bladder
  - The hypogastric nerves innervate the internal anal sphincter
  - Internal pudendal nerve ( $S_3$ – $S_4$ ) operates the external anal sphincter. Because of the common innervation, dysuria is a common complaint associated with rectal disorders



# 10-Step Approach

- Overlooked
  - Practitioners do not know how to interpret findings
  - Timely

## **#1 most important step: TAKE A GOOD HISTORY**

- Indications for rectal exam
  - Gastrointestinal bleeding
  - Rectal pain
  - Diarrhea
  - Abdominal pain
  - Nausea and/or vomiting
  - Fecal incontinence
  - Constipation
- Contraindications
  - Immunocompromised patients

# Equipment

- Disposable gloves
- Lubricant jelly
- Q-tip or gauze
- Adequate light
- Healthcare team member of same sex as the patient if performing a DRE on a member of the opposite sex or in general





# 10 Step Approach

## STEP 1

*Reassure the patient and explain what you are about to do and why*

## STEP 2: Position

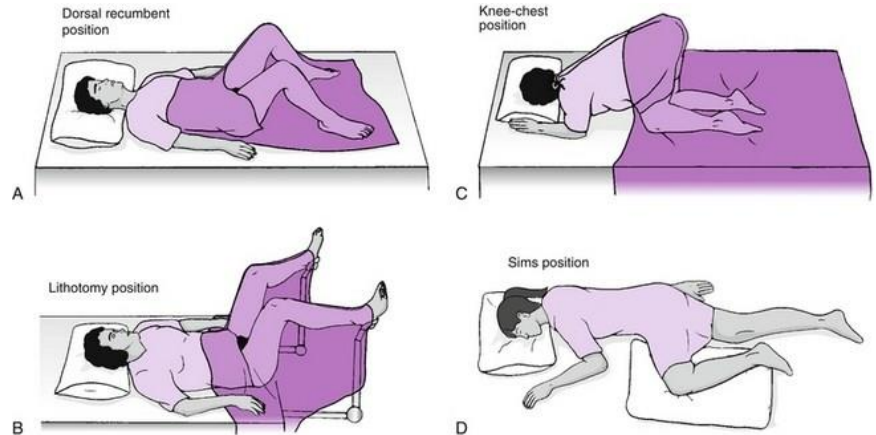
### 1. Sims position \*PREFERRED\*

- Hips flexed to 90 degrees
- Left lateral

### 2. Knee chest position

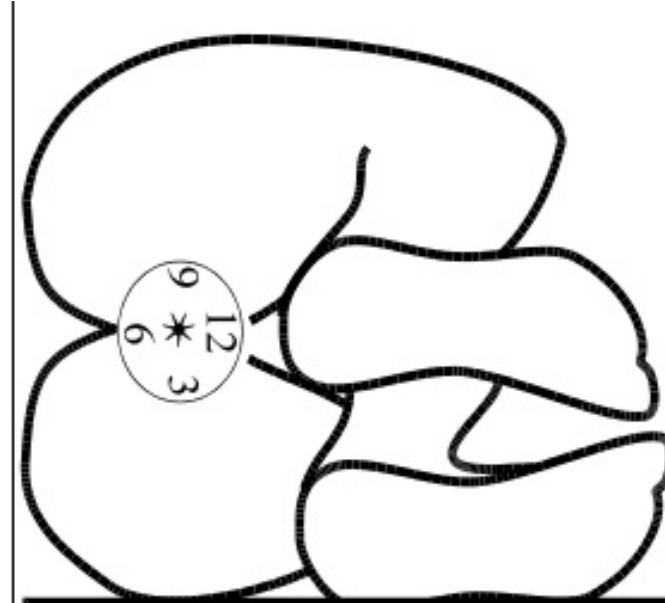### 3. Dorsal recumbent

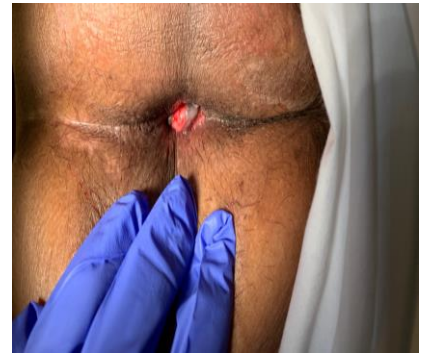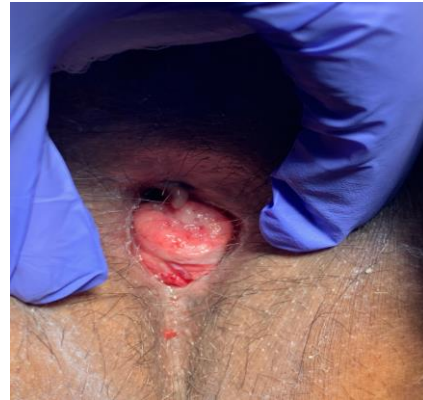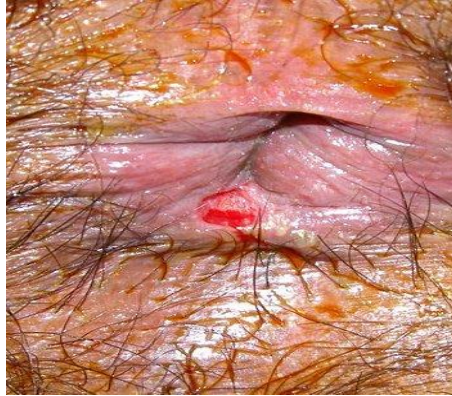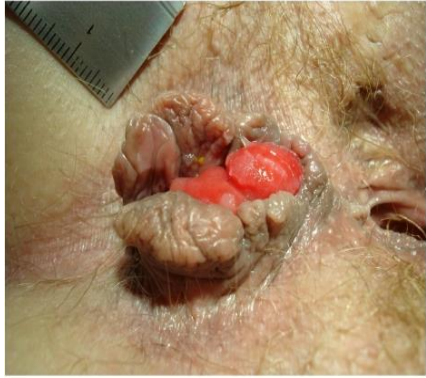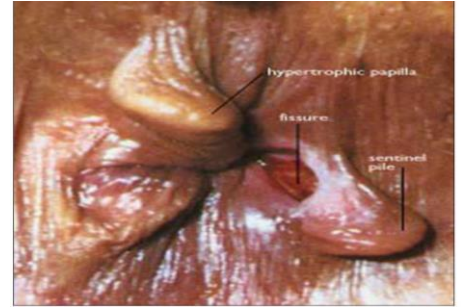
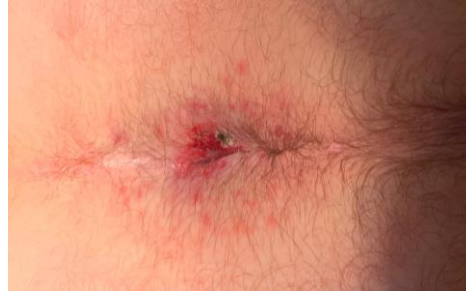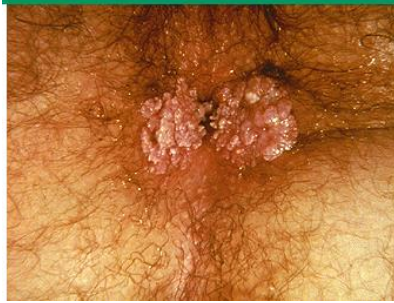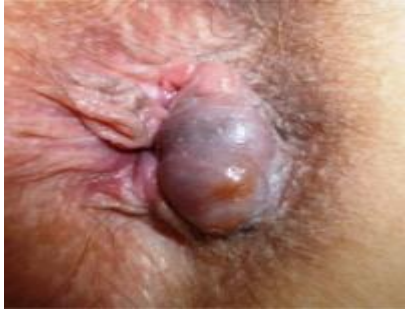### 4. Lithotomy position



# STEP 3: Inspection

- Look at the perineum by spreading the buttocks after donning a pair of gloves
- Abnormalities such as:
  - Scars (obstetric or previous surgery)
  - Thrombosed external hemorrhoids
  - Skin tags
  - Rectal prolapse
  - Anal fissure
  - Anal warts
  - Evidence of pruritus ani usually from fecal soiling
- The position of an anal lesion is described in relation to a clock
- The anterior aspect of the anus is assigned 12 o'clock

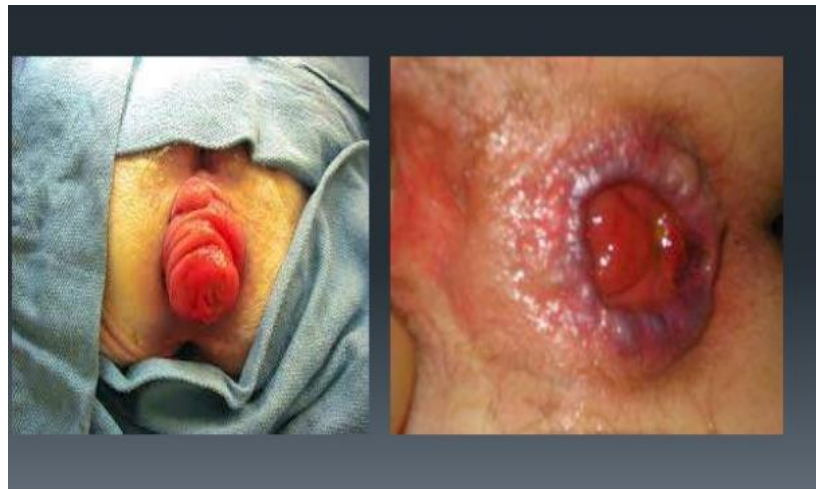



## **STEP 4:** Ask the Patient to Push and Bear Down (Valsalva Maneuver)

### **Watch the perineum**

- You may see leakage of stool
- Gaping anus often indicates lower resting pressures
- You may see prolapse of internal hemorrhoids
- On straining, if there is rectal prolapse
  - Dark red mass at anal verge
  - Radial folds are seen in mucosal prolapse (partial)
  - Concentric folds in complete prolapse
    - The mass is continuous with the perianal skin
    - It is usually painless
    - You can feel the prolapsed mucosa between the thumb and forefinger



# STEP 5: Test the Anal Wink

- Anocutaneous reflex
  - Stroke a cotton pad in all four quadrants around the anus
  - Usually you will see a brisk anal contraction
- The absence of an anal wink, particularly in the setting of fecal incontinence, should make you suspicious that there is a possible spinal cord problem
  - This should direct you to perform a more detailed neurological examination and consider further investigations accordingly

# STEP 6: Palpation

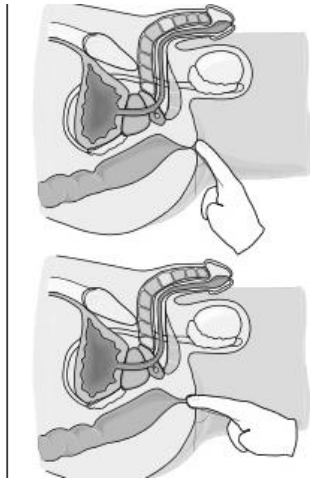
1. Place the tip of your gloved, index finger gently over the anus
2. Ask the patient to breathe and try to relax; this acts as a distraction
3. By slowly increasing pressure with the pulp of the finger, the anal sphincter usually relaxes slightly at which time the finger can be painlessly advanced into the rectum
  - If there is excruciating pain on starting the examination, this strongly suggests that there is an anal fissure and you should not proceed with the rest of the exam

Other causes of significant anal pain during palpation include:

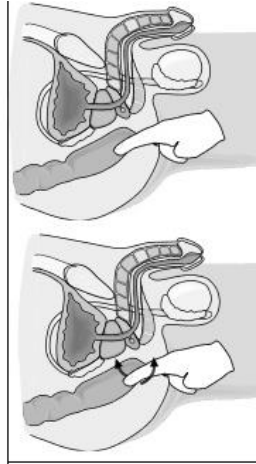
- Thrombosed external hemorrhoids
- Ischiorectal abscess
- Active proctitis
- Anal ulceration

# Palpation

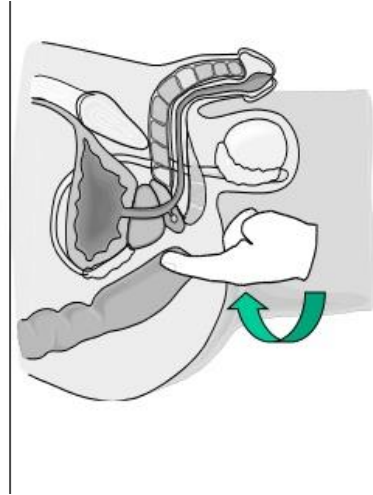
Step 1.



Step 2.



Step 3.



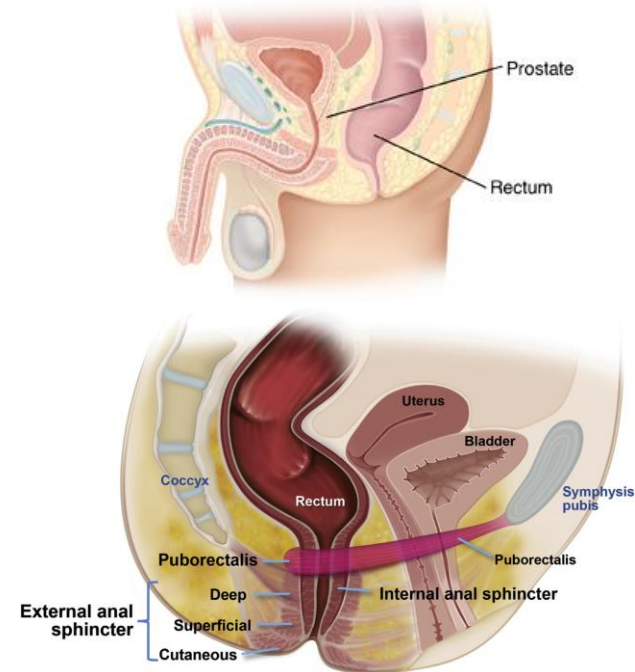
# **STEP 7: Assess Resting Sphincter Tone and Squeeze Anal Tone**

- As you are moving your finger through the rectum initially, you can gauge resting tone, which is predominantly (70–80%) attributable to the internal anal sphincter muscle
  - Presence of reduced sphincter tone, may indicate a sphincter tear
  - High anal resting tone indicates hypertonic pelvic floor
  - There appears to be a good correlation between absent, decreased, and normal resting and squeeze pressures with anorectal manometry
- Ask the patient to squeeze and hold the squeeze for as long as possible



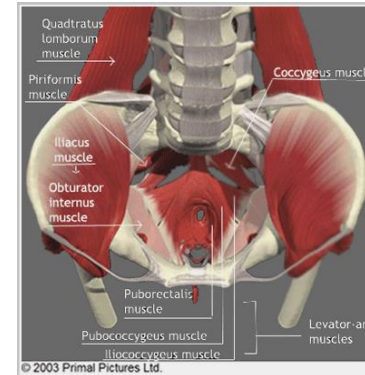
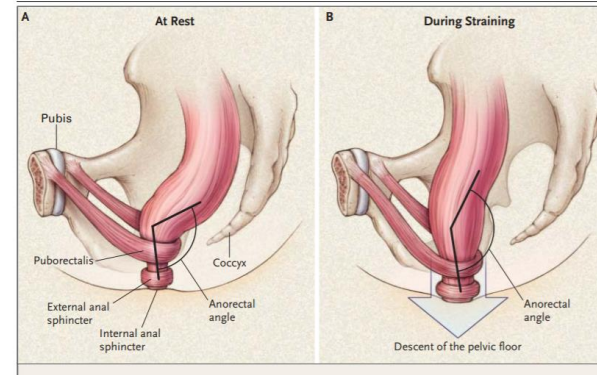
# STEP 8: Palpate the Rectal Walls

- The anterior wall is palpated for the prostate gland in men and the cervix in women.
- Rotate the finger clockwise so the lateral walls and posterior walls can be palpated in turn
- Then advance the finger high into the rectum and slowly withdraw it along the wall
  - This approach will help identify lesions such as polyps or rectal cancer if they are large enough and in reach
- Determine if there may be a rectocele or intussusception
  - Rotate your examining finger anteriorly. You may feel a defect in the anterior wall of the rectum which suggests a large anterior rectocele



# STEP 9: Assessing for Pelvic Floor Dysfunction

- Place the left hand over the patient's abdomen and assess the push effort
- Ask the patient to strain and try to push out your finger out
- Note if palpation produces pain when pressing on the posterior rectal wall
  - This suggests puborectalis muscle tenderness, which can also occur in pelvic floor dyssynergia
  - Coccygodynia – squeeze coccyx between forefinger and thumb
- Assess whether the anal sphincter and the puborectalis contract when you ask your patient to contract or squeeze the pelvic floor muscles
  - Puborectalis contraction is perceived as a “lift,” that is, the muscle lifts the examining finger toward the umbilicus
  - Many patients with fecal incontinence cannot augment anal pressure when asked to squeeze



# Pelvic Floor Dyssynergia

- 4 patterns of dyssynergia found on anorectal manometry
- The balloon expulsion test should be included in the work-up of dyssynergia
- A study by Rao et al. showed that rectal examination could identify 76% of patients with dyssynergia
  - The sensitivity and positive predictive value for diagnosing dyssynergia with digital rectal examination was 81% and 99%, respectively, making it a good screening test for dyssynergia

## Patterns of dyssynergia

Type 1	Normal push effort with paradoxical contraction of the anal sphincter
Type 2	Poor push effort with paradoxical contraction of the anal sphincter
Type 3	Normal push effort with incomplete or absent relaxation of the anal sphincter
Type 4	Poor push with incomplete anal relaxation

# STEP 10: Finishing up

- Remove the finger and inspect for obvious blood, mucus or pus, and note the feces color
- Guaiac testing (NOT RECOMMENDED)
  - Occult blood test on normal-appearing feces obtained by rectal examination probably yields such high rates of false positive and false negative reactions that it is of little value in the detection of colorectal neoplasia
- In acute gastrointestinal bleeding, it helps to know what the stool looks like
  - AVOID description “heme positive”
  - Record its gross appearance

# Documentation

---

- Describe your findings
- Comment on anus inspection
- Anal tone
- Rectal walls
- Contents of rectum (blood, melena, etc.)
- Any abnormal masses palpated
- Describe your findings as descriptive as possible size, position and shape of swelling, etc.

# Thank You!

## Questions?

### Digital Rectal Exam

